

# Hypospadias, diverticulum, and agenesis in the penile shaft of a goat kid (*Capra hircus*)

Arash Omid  · Sara Monjezi · Abolghasem Nabipour

Received: 20 August 2010 / Accepted: 1 December 2010 / Published online: 7 January 2011  
© Springer-Verlag London Limited 2011

**Abstract** The purpose of this study is to report a rare congenital urinary tract anomaly in a goat kid. A 2-day-old male goat (*Capra hircus*) showed depression, inappetence, pain, vocalizing, and the existence of a small bag at the bottom of the abdominal region. Physical examination revealed the absence of fever, increased heart rate, and increased breathing rate. The urinary tract was absent in the anterior part of the urethra (agenesis). Urine was contained in the penile urethral diverticulum. The urethral process was absent. A slot on the diverticulum was created with a surgical blade. The gap was not sutured. The kid was treated with antibiotic and anti-inflammatory drugs. Ten days later, the kid was reexamined, and the edges of the urine output gap in the bottom of the diverticulum were relieved. Urine passed readily from this opening, and clinical symptoms were absent.

**Keywords** Diverticulum · Hypospadias · Male kid · Urethra


## Introduction

Congenital urinary tract anomalies in farm animals are rare. The most common anomalies are patent urachus, hypospadias, and renal agenesis (Temizosylu 2005). Hypospadias is an uncommon congenital defect of the urinary tract. Urethral diverticulum in kids is reported infrequently (Temizosylu 2005). Hypospadias is rare in calves (Saunders and Ladds 1978; Javdani Gandomani et al. 2009), lambs (Kumi-Diaka and Osori 1979), kids (Temizosylu 2005), rams (Gilanpour 1971; Smith et al. 2006), dogs (Ader and Hobson 1978; Hayes and Wilson 1986), cats (King and Johnson 2000), monkeys (Harrison 1976), and humans (Baskin 2000). In a survey of the occurrence of congenital anomalies in goats, the occurrence of congenital hypospadias was 0.066% (Al-Ani et al. 1998). In a 4-year survey of reproductive problems in bulls and small ruminants, five cases of hypospadias have been observed, and one of them was in a goat. (Kumi-Diaka and Osori 1979).

## Case history

A 2-day-old male goat kid (*Capra hircus*) with a history and symptoms of depression, inappetence, pain, vocalizing, and the existence of a small bag in the bottom of the abdominal region was referred to the first author in the

---

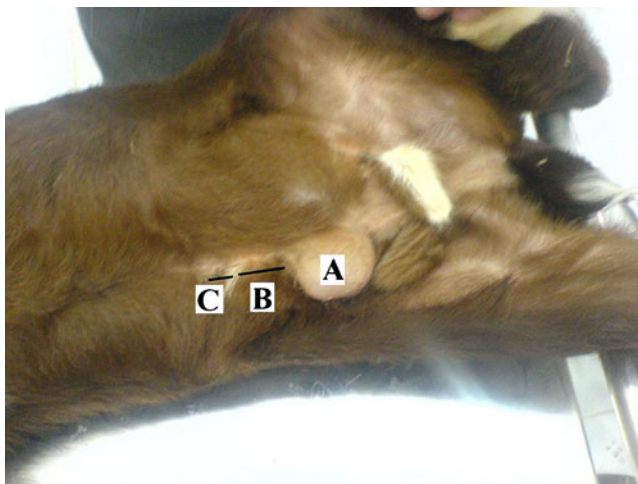A. Omid   
Department of Animal Sciences, Faculty of Agriculture,  
University of Birjand,  
P. O. box 97175-331, Birjand, Iran  
e-mail: arashomidi2@gmail.com

S. Monjezi · A. Nabipour  
Department of Anatomical Sciences,  
Faculty of Veterinary Medicine, Ferdowsi University of Mashhad,  
P. O. box 91775-1793, Mashhad, Iran

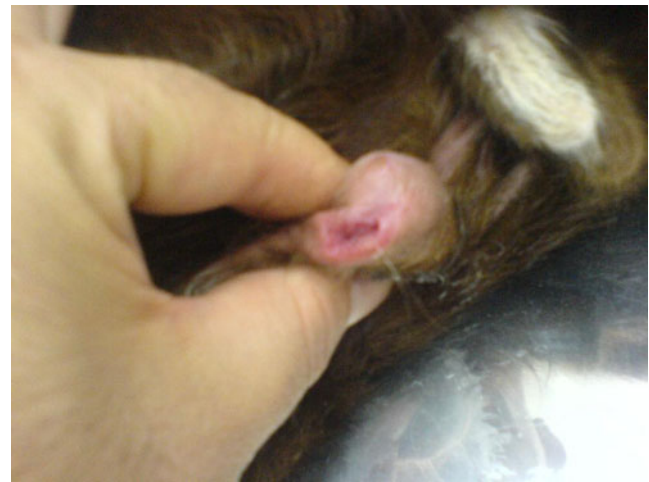S. Monjezi  
e-mail: smonjezi@gmail.com

A. Nabipour  
e-mail: nabipur@ferdowsi.um.ac.ir

Department of Animal Science, Faculty of Agriculture, Birjand University, Birjand, east Iran. Absence of fever (39.4°C) and increased heart rate (142 beats per minute) and breathing (30 breaths per minute) were noticed (Radostits et al. 2007). The most interesting finding was that the urinary tract was absent in the anterior part of the penile urethra (agenesis). In addition, the urethral process was absent, and a penile urethral diverticulum full of urine was present. First, the presence of a stone and urinary tract obstruction were evaluated. Passing a catheter from the opening of the channel determined that the urethra was not formed in area B, and an opening was present in district C (Figs. 1 and 2). Two hours later, the diverticulum was emptied with a needle. The kid was again examined (Fig. 2). Some urine in the bag had been gathered. For treatment, the kid was restrained in dorsal recumbency and was prepared for aseptic surgery. Sedation was provided with xylazine hydrochloride. After local anesthesia with lidocaine, a slot on the diverticulum was created with a surgical blade under sterile conditions. The location gap was not sutured, and the urine exit was open. The kid was treated for 5 days with an antibiotic (enrofloxacin) and for 2 days with an anti-inflammatory agent (flunixin meglumine). In a clinical examination 10 days after surgery, edges of the urine output gap in the bottom of the diverticulum were relieved; urine passed through this opening without a problem. The kid was in good health, and 3 months later, he was alive. Given the absence of part B in the penile urethra and the existence of the posterior parts, hypospadias appeared to create the diverticulum (Fig. 1). In reviewing case reports, these



**Fig. 1** A bag containing urine (penile diverticulum; a), where the urinary tract was not formed (agenesis; b); the penile urethral channel was open (c)



**Fig. 2** Two hours after complete removal of the urine with a needle, the bag contained urine again. Pay attention to the lack of a urethral process

modes together have not been expressed, and this is the first report of Iran. There are several possible explanations for this phenomenon. The etiology of hypospadias is not well understood. Hypospadias could be multifactorial and genetic; endocrinological and environmental factors could be associated with it (Sakhaee and Azari 2009). Penile hypospadias arises from the disruption of the closure of the urethral groove. The urethral groove was closed in the posterior part through mergers of the genital swellings and in the anterior part through the closure of the urethral folds near the glans. Destructive effects of genetic factors and hormone therapy with progesterone during the first month of pregnancy were involved. Modified synthesis of testosterone or anomaly of the hormone receptors can also be blamed. The multifactorial etiology of hypospadias is becoming more clearly defined, with ongoing research (Silver 2000). Further studies of endocrine disrupters, mesenchymal–epithelial interactions, and mechanisms of growth of the penis could explain the causes of hypospadias (Baskin 2000). Further work on the hormonal and molecular mechanisms of development strategies could be necessary to prevent or reduce the incidence of hypospadias and to elucidate the molecular genetic mechanisms of morphogenesis (Yamada et al. 2003). Many questions regarding the etiologic agents of urinary congenital anomalies have been generated by our study. Further work will be needed to answer such questions. According to the information available, this is the first report of hypospadias and congenital diverticulum of the penis shaft in a kid from Iran. We recommend surgical treatment for animal comfort and safety.

**Acknowledgments** We would like to thank Dr James A. Duthie and Dr Wassim Tawbi for their kind and critical reading and editing of the manuscript.

## References

- Ader PL, Hobson HP (1978) Hypospadias: a review of the veterinary literature and a report of three cases in the dog. *J Am Anim Hosp Assoc* 14(6):721–727
- Al-Ani FK, Khamas WA, Al-Qudah KM, Al-Rawashdeh O (1998) Occurrence of congenital anomalies in Shami breed goats: 211 cases investigated in 19 herds. *Small Rumin Res* 28(3):225–232
- Baskin LS (2000) Hypospadias and urethral development. *J Urol* 163(3):951–956
- Gilanpour H (1971) Perineal hypospadias in a ram. *Vet Rec* 88(25):657–658
- Harrison RM (1976) Hypospadias in a male rhesus monkey. *J Med Primatol* 5(1):60–63
- Hayes HM Jr, Wilson GP (1986) Hospital incidence of hypospadias in dogs in North America. *Vet Rec* 118(22):605–607
- Javdani Gandomani M, Dehghani Nazhvani S, Raayat Jahromi AR (2009) Congenital penile urethral aplasia in a 4-day old bull calf. *Iran J Vet Res Shiraz Univ* 10(1):87–89
- King GJA, Johnson EHB (2000) Hypospadias in a Himalayan cat. *J Small Anim Pract* 41(11):508–510
- Kumi-Diaka J, Osori DIK (1979) Perineal hypospadias in two related bull calves, a case report. *Theriogenology* 11(2):163–164
- Radostits OM, Gay CC, Hinchcliff KW, Constable PD (2007) *Veterinary medicine. A text book of the diseases of cattle, horse, sheep, pigs, and goats*, 10th edn. W. B. Saunders, Philadelphia
- Sakhaee E, Azari O (2009) Hypospadias in goats. *Iran J Vet Res* 10(3):298–301
- Saunders PJ, Ladds PW (1978) Congenital and developmental anomalies of the genitalia of slaughtered bulls. *Aust Vet J* 54(1):10–13
- Silver RI (2000) What is the etiology of hypospadias? A review of recent research. *Del Med J* 72(8):343–347
- Smith KCA, Brown PAC, Parkinson TJB (2006) Hypospadias in rams. *Vet Rec* 158(23):789–795
- Temizosylu MD (2005) Penile urethral diverticulum in a kid. *Ankara Univ Vet Fak Derg* 52:185–187
- Yamada GA, Satoh YA, Baskin LSB, Cunha GRC (2003) Cellular and molecular mechanisms of development of the external genitalia. *Differentiation* 71(8):445–460